

Subclavius Posticus Muscle - A Case Report

Músculo Subclavio Posticus - Reporte de un Caso

*Suruchi Singhal; **Vani Vijaya Rao & ***K. Y. Manjunath

SINGHAL, S.; RAO, V. V. & MANJUNATH, K. Y. Subclavius posticus muscle - A case report. *Int. J. Morphol.*, 26(4):813-815, 2008.

SUMMARY: A rare case of subclavius posticus muscle observed in a male cadaver is reported here. Presence of such accessory muscles have been recognized as possible causes of neurovascular compression syndromes in this region. It has been suggested by several authors that presence of accessory muscles like subclavius posticus can be a potential cause of thoracic outlet syndrome.

KEY WORDS: Subclavius posticus; Anomalous neck muscles; Thoracic outlet syndrome.

INTRODUCTION

Presence of anomalous or accessory muscles in the root of neck is of clinical significance and it is of importance to the surgeon to know before carrying out any surgical procedure in this region. Presence of such accessory muscles have been recognized as possible causes of neurovascular compression syndromes in this region. Of late some authors have suggested that presence of accessory muscles like subclavius posticus as a potential cause of thoracic outlet syndrome (Roos, 1976). A case of subclavius posticus muscle observed in a male cadaver is reported here.

MATERIAL AND METHOD

During routine dissection of the region of root of neck in a male dissection room cadaver, an accessory muscle was found extending between the upper border of the scapula and

first rib. The muscle was carefully dissected out and cleaned from end to end and its nerve supply was traced. The clavicle was detached from its sternal articulation and displaced for a better view of the anomalous muscle and its relationship to the surrounding structures. The size of the muscle was measured using a sliding caliper to the nearest millimeter.

RESULTS

The accessory muscle was found on the left side of a male cadaver in the root of the neck. The muscle belly was found to be attached to the upper border of the scapula lateral to the attachment of inferior belly of the omohyoid. The proximal end of the tendon was found attached to the costal cartilage of the first rib, deep to the subclavius. The measurements of the muscle were as follows: the total length of the muscle was 115mm; the belly of the muscle was flat and triangular measuring 60mm in length and 11mm in width. A fairly thick branch (about 1mm) from the suprascapular nerve innervated the muscle. The tendon of the muscle passed superficial to the subclavian vessels and the brachial plexus on its way to its insertion (Fig. 1).

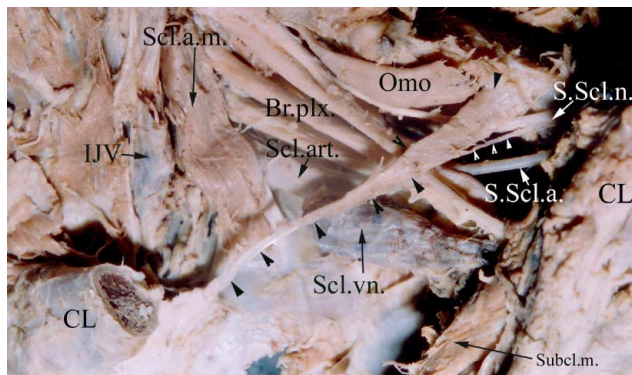


Fig. 1. Shows the subclavius posticus coursing in the root of the neck from the first rib to the upper border of the scapula. A branch from the suprascapular nerve is seen supplying the muscle belly (arrow heads). The clavicle has been cut and the omohyoid muscle has been reflected to get clear view of the muscle. Abbreviations used: Br.plx-Brachial plexus; CL-Clavicle; IJV-Internal jugular vein; Omo-Omohyoideus muscle; Scl.a.m.-Scalenus anterior muscle; Scl.art.-Subclavian artery; Scl.vn.-Subclavian vein; Subcl.m.-Subclavius muscle; S.Scl.a.-Suprascapular artery; S.Scl.n.-Suprascapular nerve.

* Assistant Professor, Department of Anatomy, St.John's Medical College, Sarjapur Road, Bangalore-560 034, India.

** Tutor, Department of Anatomy, St. John's Medical College, Sarjapur Road, Bangalore-560 034, India.

*** Professor, Department of Anatomy, St. John's Medical College, Sarjapur Road, Bangalore-560 034, India.

DISCUSSION

Aberrant muscles that connect the first rib and scapula have been reported (Shetty *et al.*, 2006; Kutoglu *et al.*, 2005). According to their location, origin and insertion they are either classified as subclavius posticus muscles or a duplication of inferior belly of omohyoid. The subclavius posticus muscle conventionally extends from the first rib to the superior border of scapula. It runs superior to the subclavian artery, subclavian vein and brachial plexus.

How ever a review of literature and the present study shows that there is considerable variation in its attachment to the scapula and its nerve supply.

Sato *et al.* (2000) *apud* Akita *et al. op cit.* propose that aberrant muscles, which run between the first costal cartilage and the upper margin of the scapula can be classified into two categories:

1. The subclavius posticus muscle, which is innervated by a branch from the nerve to the subclavius muscle.

2. A duplication of the inferior belly of the omohyoid muscle, which is innervated by a branch from the nerve to the inferior belly of the omohyoid muscle.

Akita *et al.* (1996) are of the opinion that the origin and insertion of both subclavius posticus muscle and the excess

of the inferior belly of the omohyoid muscle are similar; only the origins of the innervating branches differ. They propose that both muscles are derived from the intermediate region between the subclavius muscle and the inferior belly of the omohyoid muscle, and can be innervated by the nerve to the subclavius muscle or by the branch to the omohyoid muscle arising from the ansa cervicalis. It is suggested that these anomalies are derived from a common matrix, and are similar variations rather than different types of anomalies. Therefore, these aberrant muscles could be termed the subclavius posticus, regardless of their innervation. Tountas & Bergman, 1993 say that these muscles include the scapuloclavicularis, a small muscle passing from the root of the coracoid process and transverse scapular ligament to the back of the clavicle, and pectoralis intermedius, a fleshy slip that arises from the third and fourth ribs between pectoralis major and minor and is inserted onto the coracoid process, derived from to the fifth cervical to first thoracic myotomes.

Forcada *et al.* (2001) and Sarikcioglu & Sindel (2001) report subclavius posticus muscles innervated by branches from the suprascapular nerve. In our case, innervation is from the same source. Therefore, this innervation pattern can be added to this classification.

All the muscles regardless of their attachment on scapula and their innervation run superior to the subclavian vessels and brachial plexus hence causing compression syndromes.

Table I. Subclavius posticus muscle as described in various studies.

| Author/Year | Attachment to scapula | Attachment to first rib | Nerve supply | Relationship to structures at the root of neck |
|----------------------------------|--|-------------------------------|---|---|
| Present study (2007) | Upper border of scapula lateral to inferior belly of omohyoid muscle | Costal cartilage of first rib | Suprascapular nerve | Superficial to subclavian vessels and brachial plexus |
| Shetty <i>et al.</i> (2006) | Medial margin of suprascapular notch medial to inferior belly of omohyoid and laterally blends with the capsule of acromioclavicular joint | Costal cartilage of first rib | Nerve to Subclavius | Superficial to subclavian vessels and brachial plexus |
| Kutoglu <i>et al.</i> (2005) | Upper border of scapula lateral to inferior belly of omohyoid muscle | Costal cartilage of first rib | Suprascapular nerve | Superficial to subclavian vessels and brachial plexus |
| Sarikcioglu <i>et al.</i> (2001) | Superior angle of scapula | Costal cartilage of first rib | Suprascapular nerve | Superficial to subclavian vessels and brachial plexus |
| Forcada <i>et al.</i> (2001) | Upper margin of scapula and transverse scapular ligament | Costal cartilage of first rib | Suprascapular nerve | Superficial to subclavian vessels and brachial plexus |
| Akita <i>et al.</i> (2000) | Superior margin of scapula just mediocaudal to inferior belly of omohyoid muscle | Costal cartilage of first rib | Nerve to inferior belly of omohyoid, accessory phrenic nerve (in 1 case), nerve to subclavius | Superficial to subclavian vessels and brachial plexus |
| Akita <i>et al.</i> (1996) | Upper margin of scapula | Costal cartilage of first rib | Nerve to subclavius | Superficial to subclavian vessels and brachial plexus |

Anatomic variations at thoracic outlet region frequently cause vascular and/or nerve compression. The Paget-von Schrotter syndrome is one type of symptom complex of the thoracic outlet syndrome, and is recognised as spontaneous or effort-related thrombosis of the axillosubclavian vein (Sievert *et al.*, 1991). It is noted that subclavian vein is compressed between the subclavian muscle and the first rib during the movements of abduction

or retraction of the shoulder (Terfold & Mottershead, 1948).

By careful examinations, using MR imaging of the suprascapular region, such aberrant muscles may be diagnosed. It is recommended to take into account the possible existence of these during the examinations of patients with thoracic outlet syndrome, especially in those with symptoms of venous compression.

SINGHAL, S.; RAO, V. V. & MANJUNATH, K. Y. Músculo subclavio posticus - reporte de un caso. *Int. J. Morphol.*, 26(4):813-815, 2008.

RESUMEN: Es reportado un caso raro de músculo subclavio posticus observado en un cadáver de sexo masculino. La presencia de tales músculos accesorios ha sido reconocida como posible causa de los síndromes de compresión neurovascular en esta región. Varios autores han sugerido que la presencia de músculos accesorios como subclavio posticus, puede ser una causa potencial del síndrome de salida torácica.

PALABRAS CLAVE: Subclavio posticus; Músculo anómalo del cuello; Síndrome de salida torácica.

REFERENCES

- Akita, K.; Ibukuro, K.; Yamaguchi, K.; Heima, S. & Sato, T. The subclavius posticus muscle: a factor in arterial, venous or brachial plexus compression? *Surg. Radiol. Anat.*, 22:111-5, 2000.
- Akita, K.; Tsuboi, Y.; Sakamoto, H. & Sato, T. A case of muscle subclavius posticus with special reference to its innervation. *Surg. Radiol. Anat.*, 18:335-7, 1996.
- Forcada, P.; Rodriguez-Niedenfuhr, M.; Llusà, M. & Carrera, A. Subclavius posticus muscle: supernumerary muscle as a potential cause for thoracic outlet syndrome. *Clin. Anat.*, 14:55-7, 2001.
- Kutoglu, T.; Ulucam, E. & Gurbuz, H. A case of the subclavius posticus muscle. *Trakia J. Sci.*, 3(1):77-8, 2005.
- Roos, D. Congenital anomalies associated with thoracic outlet syndrome. Anatomy, symptoms, diagnosis and treatment. *Am. J. Surg.*, 132:771-8, 1976.
- Sarikcioglu, L. & Sindel, M. A case with subclavius posticus muscle. *Folia Morphol.*, 60(3):229-31, 2001.
- Shetty, P.; Pai, M. M.; Prabhu, L.; Vadagaonkar, R.; Nayak, S. R. & Shivanandan, R. The subclavius posticus muscle: its phylogenetic retention and clinical relevance. *Int. J. Morphol.*, 24(4):599-600, 2006.
- Sievert, T.; Maiké, H. W. & Wildmeister, W. Paget-von Schroetter syndrome: case description in the light of the literature. *Z. Gesamte Inn. Med.*, 46:375-80, 1991.
- Terfold, E. D. & Mottershead, S. Pressure on the cervico-brachial junction (an operative and anatomical study). *J. Bone Joint Surg.*, 30B:261-3, 1948.
- Tountas, C. & Bergman, R. *Anatomic variations of the upper extremity*. Churchill Livingstone, New York, 1993. pp.223-4.

Correspondence to:
Dr K. Y. Manjunath,
Department of Anatomy
St. John's Medical College
Sarjapur Road
Bangalore-560 034
INDIA

E-mail:kymanjunath@rediffmail.com

Received: 14-02-2008

Accepted: 17-08-2008

