

Shape, Septa and Scalloping of the Maxillary Sinus

Forma, Septo y Festoneado del Seno Maxilar

C, Rennie¹; M.R. Haffajee² & K. S. Satyapal¹

RENNIE, C.; HAFFAJEE, M. R. & SATYAPAL, K. S. Shape, septa and scalloping of the maxillary sinus. *Int. J. Morphol.*, 35(3):970-978, 2017.

SUMMARY: The maxillary sinus varies according to age, however there are limited studies that have illustrated its 3D form over time. This study aimed to classify the maxillary sinus by the shape, number of septa and scallops in a 1 to 25 year age group, utilising computerized tomography (CT) scans and 3D reconstruction. CT scans (n=480) were reviewed from the picture archiving and communication system (PACS) of the state and private hospitals in Pietermaritzburg and Durban KwaZulu- Natal (KZN), South Africa. The sample consisted of 276 males and 204 females, 1-25 years and of two population groups, black African and white. SLICER 3D (www.slicer.org) was utilised in order to reconstruct a 3D model of the sinus. Morphological traits such as the presence of the sinus, scalloping and septa within the sinuses were categorised. In addition, the shape of the 3D model of the sinus was analysed anteriorly (coronal) and laterally (sagittal) adapting the classifications by Kim (1962) and Kim *et al.* (2002). The maxillary sinus was present bilaterally in n=477 individuals (99.4 %). Five different anterior shapes viz. Type 1 (triangular), Type 2 (upside down triangle), Type 3 (square), Type 4 (irregular) and Type 5 (rectangular) were identified in the anterior view. This shape was associated with age and population groups (p<0.05). In the lateral view, the maxillary sinus appeared to be quadrilateral with differences noted along the inferior wall. Intrasinus maxillary septa were more evident in the anterior region of the maxillary sinus (27.9 % right; 28.5 % left). The maxillary septa were commoner in females (37.9 % right; 39.4 % left) than in males (28.5 % right; 30.3 % left). They were also more commonly observed in the white cohort (63.8 % right; 68.1 % left) than in the black African cohort (29.1 % right; 30.5 % left). Scalloping in the axial plane from above along its anterior margin was also observed. An in-depth classification of the morphology of the 3D form of the maxillary sinus according to age (1 to 25 years) was established. Five different shapes in both the anterior and lateral view of the 3D model were observed. Anteriorly, it was noted that the main shape was Type 2 (upside down triangle). The shape of the sinus changed in the form according to age. Laterally, the shape was related to the development of the teeth, as the inferior wall of the sinus was classified. Maxillary septa and scalloping of the sinus were reported in all age groups. Surgically, the sinus morphology is essential for dental procedures such as sinus augmentation or dental implants, and anthropologically, in forensic identification.

KEY WORDS: 3D reconstruction; Morphology; Shape; Maxillary sinus.

INTRODUCTION

The maxillary sinus, also known as the “Antrum of Highmore”, is located in the body of the maxilla on either side of the nasal cavity (Laitman, 2008). It is the largest of the paranasal sinuses, contributing to the form of the face (Fernandes, 2004). It may vary according to population groups and sex (Fernandes). Anatomical textbooks describe the sinus as pyramidal in shape composed of four walls, a base formed by the lateral wall of the nose, and an apex that extends into the zygomatic process (Standring, 2016). Fernandes defined the sinuses according to four different shapes, using shape coefficients illustrated by Anagnostopoulou *et al.* (1991, cited by Fernandes).

However, Fernandes concluded that this shape classification was not a good ethnic or sex predictor. Most of the sinuses had a parabolic-hyperbolic shape irrespective of ethnic or sex grouping. Furthermore, Fernandes noted that there might be a slight confounding effect between population and age groups, as their study was solely adults.

Wolf *et al.* (1993) suggested that the maxillary sinus shape adjusted according to age, which was later confirmed by Jun *et al.* (2005). The study by Jun *et al.* of 3D reconstructed images of 173 patients aged between 1 to 70 years reported that the maxillary sinus changed

¹ Department of Clinical Anatomy, School of Laboratory Medicine and Medical Sciences, College of Health Sciences, University of KwaZulu-Natal, Westville Campus, Private Bag X54001, Durban, South Africa.

² Ethekweni Hospital and Heart Centre, Durban, South Africa. Emergency Medicine Medical Officer and Ex Professor Clinical Anatomy. South Africa.

into a reverse pyramidal shape as age progressed. A radiological survey of more than 500 Korean patients demonstrated that the pyramidal form of the maxillary sinus with the upper side wider was present in 52.4 %, the lower side wider in 42.4 %, horizontal in 4 % and multiple shaped in 1.2 % (Kim). A more recent study by Kim *et al.*, using three dimensional reconstructed images of Dentascans and CT images, analysed the shape of the maxillary sinus, categorising its inferior wall of the sinus into six categories. This again did not take into account age, sex or ethnic differentiation.

In 1910, Underwood, noted bony cortical structures that traversed the maxillary antrum inferiorly and named them maxillary septa (Orhan *et al.*, 2013). The author noted their location in the anterior, middle and posterior regions of the sinus, and they appeared to have a relation to tooth development (Malec *et al.*, 2014). Most studies confirm this and noted that maxillary septa are of importance during dental implantations and sinus lifts as their presence may complicate these procedures (Malec *et al.*, 2015). According to Orhan *et al.*, very few studies have discussed the prevalence of these structures in children.

It is apparent from the literature reviewed that there still exists a paucity of studies that have illustrated the morphological traits of the maxillary sinus, particular its 3D form and these features over time. Therefore, this study aimed to illustrate and classify the morphology of the maxillary sinus from 1 to 25 years of age focusing on the shape, septa and scalloping of the sinus according to sex and population groups.

MATERIAL AND METHOD

Computerized tomography (CT) scans of approximately 7000 patients below 25 years, as normal pneumatization may be complete until this period (Adibelli *et al.*, 2011) were reviewed from the picture archiving and communication system (PACS) of the state hospital, Greys Hospital, and the archives of radiologists Jackpersad and Partners, Specialist Diagnostic Radiologists (EtheKweni Hospital and Heart Centre and Isipingo Hospitals) in Pietermaritzburg and Durban KwaZulu- Natal (KZN), South Africa. Ethical clearance was obtained from the University of KwaZulu- Natal Biomedical Research Ethics Committee (BE247/11) and the Department of Health, KZN.

Inclusion Criteria: a) patients between 1-25 years of age b) images without observable signs of abnormal pathological processes of the paranasal sinuses c) slice thickness <1.25mm

d) non-distorted images and e) the largest population groups attending the state and private hospitals above. A final suitable sample of n=480 patients that satisfied these criteria was obtained. The sample consisted of 276 males and 204 females, all between the ages of 1-25 years old (mean age 14.5 years) and of two population groups (black African n=433 and white n=47). The sinus images of each patient were of slice thickness between 0.625 to 1.25mm in the axial plane, and were imported to SLICER 3D (www.slicer.org) in order to reconstruct a 3D model of the sinus. The coronal view was selected as the most convenient and easiest method to outline the sinus per slice as per Holton *et al.* (2013). A 3D model of the maxillary sinus bilaterally and unilaterally was then reconstructed. The shape of the sinus of these 3D forms were analysed in the anterior (coronal) and lateral (sagittal) views according to the classifications of Kim and Kim *et al.* respectively. Variations, if present were noted. Other morphological traits such as the presence of the sinus, scalloping along the anterior margin and the prevalence of the intrasinus (maxillary) septa were observed as well.

Statistical Analysis. Cross tabulations (to tabulate the frequencies of the parameters) and the Pearson chi square test were adopted in the study utilising the Statistical Package for social sciences SPSS version 24.0 (IBM® SPSS Inc., Chicago, Illinois, USA). A P-value less than 0.05 was considered statistically significant. The age range of 1-25 years was conveniently subdivided into eight three-year cohorts viz. 1-3; 4-6; 7-9; 10-12; 13-15; 16-18; 19-21; 22-25 to observe the shape of the sinuses and to compare differences between the variables. The age categories approximated that according to the Adibelli *et al.* study. The frequency of the morphological parameters was expressed as a count and a percentage. The Pearson chi square test was used to show the association between the morphological characteristics and age, sex and population.

RESULTS

Presence/Absence of the maxillary air sinus. The maxillary sinus was present bilaterally in n=477 individuals (99.4 %) and absent bilaterally in n=3 individuals (0.6 %). Absence of the sinus occurred from the 1 to 3 years of age. The sinus was present on both sides in males n=274 (99.3 %) and females n=203 (99.5 %); in black African n=433 (99.3 %) and white n=47 (100 %).

Shape of the maxillary sinus

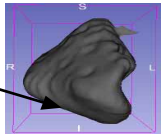
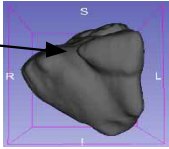
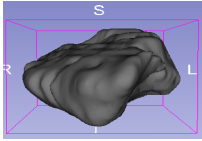
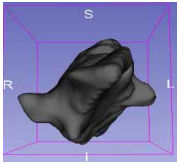
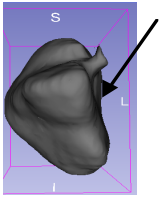
Anterior View. In 3 individuals there was no sinuses present and the remaining sample was analysed and reflected five

different shapes viz. Type 1 (triangular), Type 2 (upside down triangle), Type 3 (square), Type 4 (irregular) and Type 5 (rectangular). The five different shapes are illustrated in Table I. Overall, the main shape identified was Type 2 (49, 4 % R; 48.3 % L) followed by Type 1 (23.3 % R; 21.9 % L) and Type 5 (18.5 % R; 99.4 % L).

In males and females, the main shape identified on the right and left sides was Type 2 (49.6 % R; 46.7 % L) and

(49.8 % R; 51.2 % L) respectively. In males, this was followed by Type 1 (23.0 % R; 23.4 % L) and Type 5 (17.9 % R; 18.2 % L), and in females, Type 1 (24.1 % R; 20.2 % L) and Type 5 (19.7 % R; 20.2 % L). Type 2 was the main shape identified in black African (47.9 % R; 46.5 % L), and in the white population group (66.0 % R; 68.1 % L). There was no association between sex and shape (anterior view), but, there was an association found between shape and the population groups ($p < 0.001$) (Table I).

Table I. Classification of the varying 3D shapes of the maxillary air sinus (Anterior view)

3D Shape	Description of shape	RIGHT (n=477)				LEFT (n=477)			
		M	N (%)			M	N (%)		
			F	B	W		F	B	W
Inferior wall	 <i>Triangular- the inferior wall is wider</i>	63 (23.0)	49 (24.1)	97 (22.6)	15 (31.9)	64 (23.4)	41 (20.2)	92 (21.4)	13 (27.7)
Superior wall	 <i>Upside down triangle- superior wall is wider</i>	136 (49.6)	101 (49.8)	206 (47.9)	31 (66.0)	128 (46.7)	104 (51.2)	200 (46.5)	32 (68.1)
	 <i>Square- all walls appear to be similar in size</i>	14 (5.1)	7 (3.4)	21 (4.9)	0 (0)	24 (8.8)	11 (5.4)	35 (8.1)	0 (0)
	 <i>Irregular</i>	12 (4.4)	6 (3.0)	18 (4.2)	0 (0)	8 (2.9)	6 (3.0)	14 (3.3)	0 (0)
	 <i>Rectangular - superior and inferior walls both appear pointed, medial and lateral walls appear to be similar in size</i>	49 (17.9)	40 (19.7)	88 (20.5)	1 (2.1)	50 (18.2)	41 (20.2)	89 (20.7)	2 (4.3)
	p-value		0.825		0.001		0.560		0.001

Note the air sinus is absent in 3 individuals (age 1-3)

The shape of the maxillary sinus on both sides was symmetrical. There was an association between shape (anterior view) and age ($p < 0.001$). On both sides the main shape identified from 1-3 years of age was Type 5 (rectangular) (38.5 % R; 40.0 % L) followed by Type 1 (triangular) from 4 to 6 years (38.6 % R; 36.4 % L), 7 to 9 years (50.0 % R; 43.3 % L) and at 10 to 12 years of age (39.0 % R; 41.5 % L). Lastly Type 2 (upside down triangle) from 13 to 15 (69.8 % R; 60.5 % L), 16 to 18 (61.4 % R; 63.2 % L), 19 to 21 (66.3 % R; 65.2 % L) and 22 to 25 years of age (71.3 % R; 66.7 % L) (Fig. 1a-b)

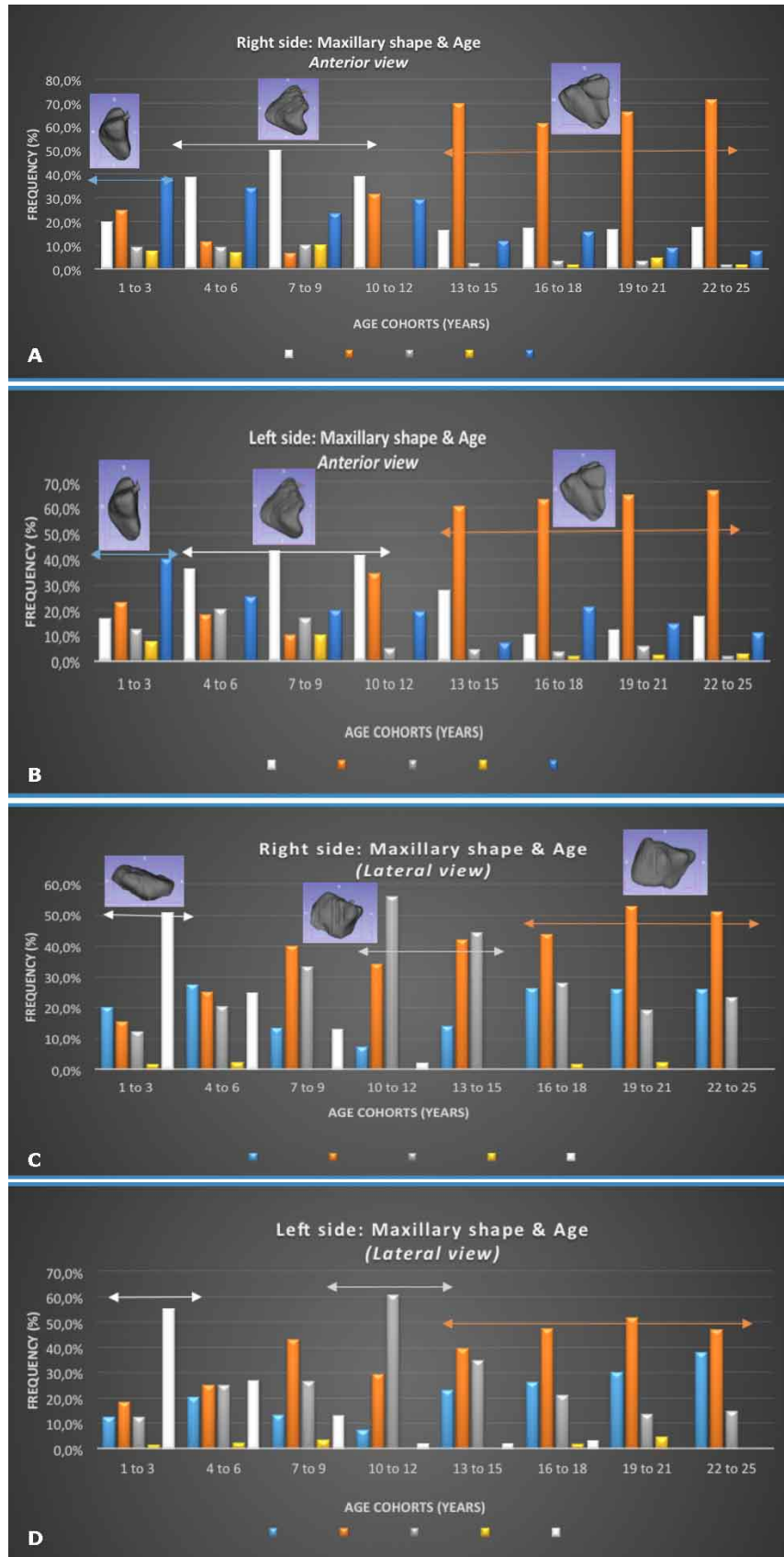
Lateral view of the maxillary sinus. Laterally, the maxillary sinus appeared to be quadrilateral with differences noted along the inferior wall according to Kim *et al.*, classification. Therefore, five different shapes were observed viz. Type 1 (inferior wall flat), Type 2 (inferior wall narrower than superior wall), Type 3 (inferior wall rounded), Type 4 (inferior wall wider than superior wall) and Type 5 (inferior wall rectangular) (Table II). Overall, the main shapes identified on the right side was Type 2 (40 %), Type 3 (26.5 %) and Type 1 (21.7 %). On the left side the main shapes observed was Type 2 (39.4 %), Type 1 (24.4 %) and Type 3 (22.3 %).

Laterally, there was no association between the shape of the maxillary sinus, sex and population

Figs. 1. A and B Graphs illustrating the distribution of Types of maxillary shape & age (Anterior view).

*The right and left sides illustrated symmetrical growth, and also indicate that there is a change in form as age progresses, from Type 5 (1-3 years) (blue double arrow) to Type 1 (from 4 to 12 years) (grey double arrow) and finally Type 2 (from 13 to 25 years) (orange double arrow).

Figs. 1. C and D. Graphs illustrating the distribution of Types of maxillary shape & age (Lateral view).



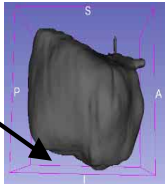


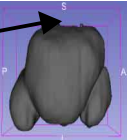
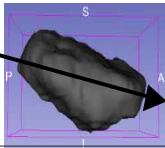
groups, ($p > 0.05$). In the male cohort on both sides, the main shapes identified laterally was, Type 2 (37.6 % R; 39.4 % L), Type 3 (28.5 % R; 22.6 % L) and Type 1 (22.6 % R; 24.5 % L). In the female cohort the main shapes were similar, Type 2 (43.8 % R; 39.9 % L), Type 3 (24.1 % R; 22.3 % L) and Type 1 (20.7 % R; 24.5 % L). In terms of the populations groups, the shapes were distributed similarly, with Type 2 noted as the main shape in the black African cohort (40.2 % R; 39.3 % L) and white (40.4 % R; 42.6 % L) (Table II).

Laterally, the shape was associated with to age (p value < 0.001). The sinuses appeared to have a symmetrical form with a few differences. The change in form was

associated with age, transforming from Type 5 (at 1-3 years) with a distinct change in shape at 10-12 years (Type 3) and finally Type 2 (from 16 to 25 years on the right side) and Type 2 (from 13 to 25 years on the left side) (Fig. 1c-d).

Septa. Intrasinus septa were observed in the maxillary sinuses (32.3 % right; 34.0 % left). They were located anteriorly, middle and posteriorly within the maxillary sinus according to Underwood's classification. Most of the septa were located in the anterior region of the maxillary sinus (27.9 % right; 28.5 % left). The septa were seen more in females (37.9 % right; 39.4 % left) than in males (28.5 % right; 30.3 % left). They were also observed more in the

Table II. Classification of the varying 3D shapes of the maxillary air sinus (lateral view).

3D Shape	Description of shape	RIGHT (n=477)				LEFT (n=477)			
		N (%)				N (%)			
		M	F	B	W	M	F	B	W
Inferior wall 	Type 1: Inferior wall flat	62 (22.6)	42 (20.7)	90 (20.9)	14 (29.8)	67 (24.5)	50 (24.6)	107 (24.9)	10 (21.3)
	Superior wall 	Type 2: Inferior wall narrower than superior wall	103 (37.6)	89 (43.8)	173 (40.2)	19 (40.4)	108 (39.4)	81 (39.9)	169 (39.3)
Posterior wall 		Type 3: Inferior wall is rounded	78 (28.5)	49 (40.2)	116 (27.0)	11 (23.4)	61 (22.3)	46 (22.7)	94 (21.9)
	Superior wall 	Type 4: Superior wall is smaller than inferior wall	2 (0.7)	3 (1.5)	4 (0.9)	1 (2.1)	4 (1.5)	4 (2.0)	7 (1.6)
Anterior wall 		Type 5: Inferior wall narrowest: Rectangular appearance	29 (10.6)	20 (9.9)	47 (10.9)	2 (4.3)	34 (12.4)	22 (10.8)	53 (12.3)
	p-value		0.583		0.303		0.977		0.607

Note the air sinus is absent in 3 individuals (age 1-3).

white cohort (63.8 % right; 68.1 % left) than in the black African cohort (29.1 % right; 30.5 % left). The highest number of septa were observed from 13 to 15 on the right side (44.2 %) and 16 to 18 years on the left side (47.4 %). The number of septa and location is reflected in Table III, and illustration of intrasinus septa in Fig. 2a.

Scalloping. The outline of the anterior margin was scalloped or lobulated and these were counted. The range was from a flat margin (0) to 4 scallops. The highest frequency was an anterior margin that was rounded (1 scallop), which was seen in 45.4 % right and 37.3 % on the left of the sample (Table IV, Fig. 2b).

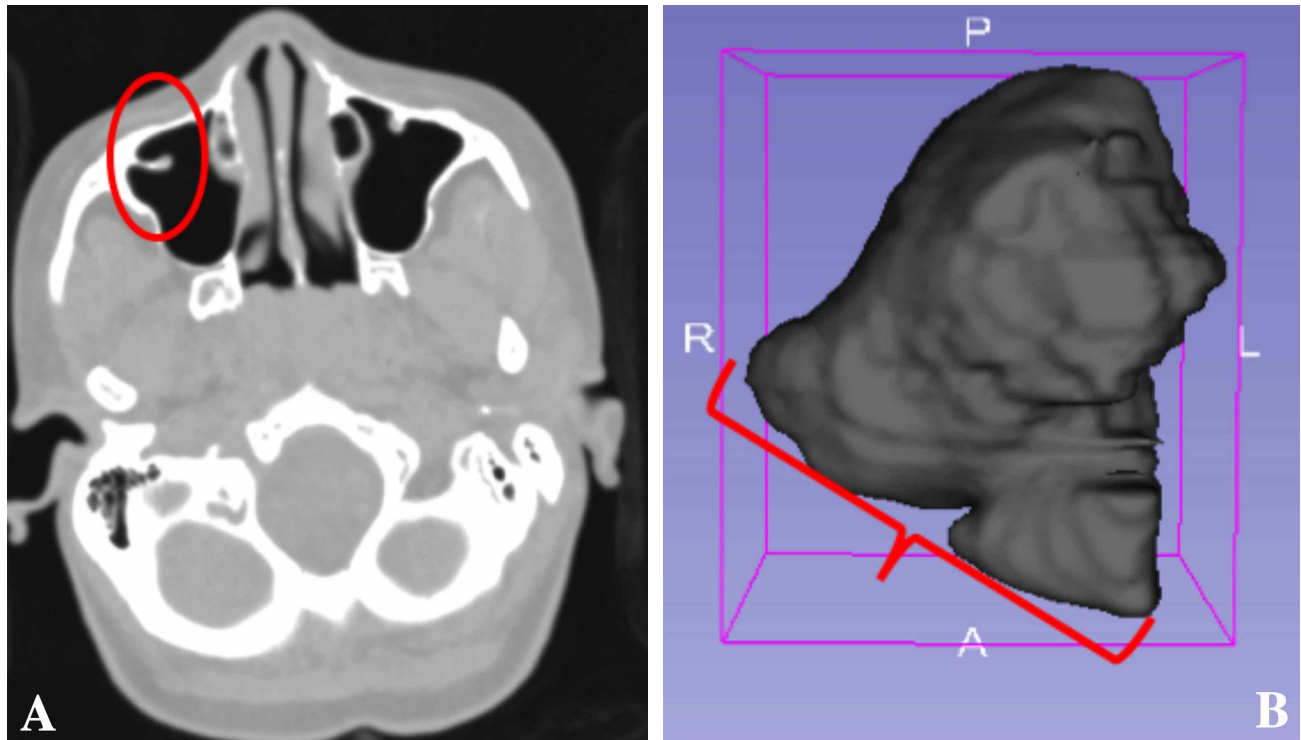


Fig. 2A. Intrasinus septa – anterior region. (outline indicates maxillary septum). Fig. 2B. Maxillary air sinus- scallops (bracket indicating scallops along the anterior margin).

Table III. Classification of maxillary intra-sinus septa.

	<i>Location and prevalence (%)</i>							
	<i>Anterior</i>		<i>Middle</i>		<i>Posterior</i>		<i>Total</i>	
	R	L	R	L	R	L	R	L
M	22.6	23.4	1.5	1.8	9.9	6.6	28.5	30.3
F	35.5	36.0	0.5	2.0	5.4	3.9	37.9	39.4
p-value	0.001	0.024	0.293	0.582	0.053	0.147	0.019	0.024
B	24.7	25.1	1.2	2.1	7.4	4.9	29.1	30.5
W	59.6	61.7	0	0	12.8	10.6	63.8	68.1
p-value	0.000	0.000	0.594	0.390	0.158	0.101	0.000	0.000
1-3 yrs	9.2	9.2	0	1.5	3.1	4.6	12.3	15.4
4-6 yrs	4.5	9.1	0	0	9.1	2.3	13.6	9.1
7-9 yrs	10.0	13.3	3.3	0	6.7	0	6.7	13.3
10-12 yrs	39.0	39.0	0	0	4.9	7.3	39.0	43.9
13-15 yrs	37.2	34.9	4.7	4.7	7.0	4.7	44.2	41.9
16-18 yrs	31.6	36.8	3.5	3.5	8.8	5.3	38.6	47.4
19-21 yrs	36.0	34.8	0	2.2	10.1	6.7	39.3	41.6
22-25 yrs	38.0	37.0	0	1.9	10.2	7.4	40.7	41.7
p-value	0.000	0.000	0.053	0.672	0.758	0.768	0.000	0.000

Key: M- Male, F- Female, B- Black African, W- White, R-right, L-left

Table IV. Frequency of scallops along the anterior margin.

<i>Number of scallops along the anterior margin of the 3D maxillary air sinus model (%)</i>										
	RIGHT (n=477)					LEFT (n=477)				
	F	1	2	3	4	F	1	2	3	4
M	14.6	46.7	32.5	6.2	0	16.1	39.8	38.7	5.5	0
F	13.3	44.3	33.5	7.9	1.0	18.7	34.5	34.0	12.3	0.5
p-value			0.550					0.032		
B	15.3	48.8	30.7	5.1	0	18.6	39.3	36.7	5.3	0
W	2.1	17.0	53.2	23.4	4.3	4.3	21.3	36.2	36.2	2.1
p-value			0.000					0.000		
1-3	44.6	46.2	7.7	1.5	0	52.3	40.0	6.2	1.5	0
4-6	25.0	61.4	13.6	0	0	34.1	50.0	9.1	6.8	0
7-9	6.7	70	20.0	3.3	0	16.7	40.0	43.3	0	0
10-12	7.3	48.8	31.7	12.2	0	9.8	34.1	43.9	12.2	0
13-15	2.3	48.8	32.6	14.0	2.3	0	34.9	48.8	16.3	0
16-18	3.5	38.6	50.9	7.0	0	8.8	40.4	40.4	10.5	0
19-21	11.2	39.3	40.4	7.9	1.1	11.2	37.1	43.8	7.9	0
22-25	8.3	38.9	44.4	8.3	0	8.3	31.5	49.1	10.2	0.9
p-value			0.000					0.000		
Total	14.0	45.4	32.7	6.9	0.4	17.1	37.3	36.5	8.3	0.2

Key: F- flat anterior border, M- Male, F- Female, B- Black African, W- White *1 to 4 indicates the range of scallops along the anterior margin

DISCUSSION

This study evaluated the morphology of the sinus utilising 3D dimensional reconstructed images from computerized tomography scans (n=480). The sample consisted of n=480 bilateral, reconstructed sinuses. The sample size was large in comparison [Fernandes (n=53) and Jun *et al.* (n=100)]. The study age range included was from childhood to early adulthood, whilst most previous studies reviewed either children (Wolf *et al.*) or adults only (Fernandes). The shape, number of septa and scalloping of the maxillary sinus was also evaluated.

In the current study, the maxillary sinus was present bilaterally in n=477 individuals (99.4 %) and absent in n=3 individuals (0.6 %). This is consistent with development of the sinus. Most anatomical textbooks note that the maxillary sinus is the first to develop from ten weeks intrauterine (Sperber, 1989). It develops from an outpouching of the lateral nasal wall of the nasal capsule in the ethmoidal area (Levine & Clemente, 2005). Initially, it is a slit like intrauterine structure limited in its development due to the growing ethmoidal cells and teeth (Levine & Clemente). However, at birth it is the largest of the sinuses and may be seen radiographically (Levine & Clemente). According to Scuderi *et al.* (1993) partial or complete opacification of the maxillary sinus may be normal in the first few years of life. This, therefore is confirmed in the current study results.

Shape of the maxillary sinus according to age, sex and population groups. Few studies analysed the shape of the maxillary sinus. These include Kim radiographic study, Fernandes’ computerized tomography study, and the three dimensional reconstruction studies utilised by both Kim *et al.* and Jun *et al.* The current study utilised three dimensional reconstructed images, and then the anterior shape classification according to Kim followed by the lateral classification shape according to Kim *et al.*, was used. Anteriorly, it was noted that the most prevalent form of the maxillary sinus bilaterally was Type 2 (upside down triangle) (49, 4 % R; 48.3 % L). This shape was seen to be prevalent in both males (49.6 % R; 46.7 % L) and females (49.8 % R; 51.2 %L) and between the population groups. There was no association between the sexes, but there was an association found in the population groups (p<0.001) and the shape anteriorly. Fernandes, who noted through utilising linear parameters (length, breadth and volume) of the sinus, that the sinus was similar in shape irrespective of sex or population group. However, only the medial antral wall of the sinus was a more useful predictor of sex and population affinity (Fernandes). Jun *et al.*’s study illustrated a difference in growth according to the size of the sinuses between male and female, but the study did not elaborate on the shape differences. The current study does compare favourably with Kim study, in which they also noted that the Type 2 was most prevalent in the Korean sample. Furthermore, the current study illustrated an additional form Type 5 rectangular shape which was not noted in Kim *et al.* study. This may be due to different radiographic techniques used and

the larger sample of children that was utilised in this work compared to Kim.

The current study, also illustrated that the sinus shape appeared to change over the period of 1 to 25 years of age, as there was an association with age ($p < 0.001$). On both sides the main shape identified from 1-3 years of age was Type 5 (rectangular) followed by Type 1 (triangular) from 4 to 12 years of age with Type 2 (upside down triangle) from 13 to 25 years of age [Fig. 1a-b]. The 3D form and changes with development appear to be consistent with literature. According to Scuderi *et al.*, the maxillary sinus shows two active pneumatization periods during its development after birth. The first period from birth to three years of age and the second period from seven to twelve years. This was also confirmed by Jun *et al.* study which illustrated that the sinus “changes into the shape of an upside down pyramid”. This, according to Jun *et al.*, may be due to the developmental changes in the structure of the craniofacial skeleton that surrounds the maxillary sinus. In addition, the rectangular form prevalent from 1-3 years of age in the current study is plausible. According to Sperber, due to bone resorption the sinus enlarges, except along the medial wall which is matched by opposing bone deposition, therefore changing its form from rectangular to triangular.

Laterally or sagittal, the sinus was viewed in relation to the inferior wall of the sinus, lying superior to the developing teeth. The current study illustrated five distinct shapes, which differed from Kim *et al.*, where six types were illustrated.

The current study illustrated no association in terms of the shape observed laterally according to sex and population groups. However, there was an association between and age. The change in shape was distinct at (1-3 years) with the first change in shape at 10-12 years (Type 3) and a final Type 2 shape (from 16 to 25 years on the right side) and a Type 2 shape (from 13 to 25 years on the left side). The study compared favourably with Kim *et al.*, as they noted that Type 2 was more prevalent in their study. The change in form seen in the current study appeared to be related with the developing teeth. Further research will be needed to evaluate the 3D shape in relation to the teeth development and eruption.

Other morphological traits (septa, scalloping). Studies indicate that the incidence of maxillary septa are between 13 %-36 %, and are mostly on the left side with a higher incidence in males (González-Santana *et al.*, 2007). Overall, the current study confirms the literature as incidence at 32.3 % on the right and 34.0 % on the left was reported. However, this study was consistent with Park *et al.* (2011), as maxillary

septa were found to be more common in the female cohort. Most authors classify the septa as according to Underwood (1910), who had suggested that they arise due to tooth development. The current study noted the highest prevalence of septa in the anterior region (27.9 % right; 28.5 % left) as with previous studies such as Malec *et al.* (2014). It is not certain as to how the maxillary septa may develop, but according to Malec *et al.* (2014), they may occur during craniofacial development in relation to the sutures found along the alveolar process and maxillary sinus, or they may be due to tooth development and masticatory forces. Other authors such as Nievert *et al.* (1930, cited by Malec *et al.*, 2014) suggest that they are embryonic outpouchings of the ethmoid infundibulum. According to Orhan *et al.* most studies have not illustrated the prevalence of septa in children and knowledge of these structures is essential in endoscopic sinus surgery. This study illustrated that they are present in all age groups and that they were most prevalent from thirteen to fifteen years of age. This may correlate with pneumatization of the sinus (Scuderi *et al.*) and may confirm Vinter’s theory that the “septa remains were the margin of two post pneumatization regression zones allowing for transfer of masticatory pressure” (Malec *et al.*, 2014).

This study also illustrated the presence of scallops along the anterior margin. Only one other study illustrated scalloping of the sinus (Shahidi *et al.*, 2016).

CONCLUSION

The current study illustrated the three dimensional form of the maxillary sinus according development within the period of 1 to 25 years of age. The sample size relatively was large in comparison with other 3D studies. The shape was analysed according to classifications by Kim & Kim *et al.* noting five different shapes in both the anterior and lateral views. Anteriorly, it was noted that the main shape was Type 2 (upside down triangle). The shape was associated with population and age, meaning that the form was different according to these two variables. Laterally, the shape seemed to be related to the development of the teeth, as the inferior wall changed in form as the age progressed. However, the shape laterally, was not associated with sex or population groups. In addition, maxillary septa and scalloping were present and classified in all age groups. These structures were more common in the anterior region, and in females. The maxillary morphology is important during planning of dental procedures such as dental implantation and sinus augmentation (Malec *et al.*, 2014), as well as anthropologically in forensic identification such as age or population affinity.

RENNIE, C.; HAFFAJEE, M. R. & SATYAPAL, K. S. Forma, septo y festoneado del seno maxilar. *Int. J. Morphol.*, 35(3):970-978, 2017.

RESUMEN: El seno maxilar varía según la edad, sin embargo existen pocos estudios que hayan ilustrado su forma tridimensional. El objetivo de este estudio fue clasificar el seno maxilar por su forma, número de septos y las vieiras en un grupo de 1 a 25 años, utilizando tomografías computarizadas (TC) y reconstrucción 3D. Las tomografías computarizadas (n = 480) fueron revisadas del sistema de archivo y comunicación de imágenes (PACS) de los hospitales estatales y privados de Pietermaritzburg y Durban KwaZulu- Natal (KZN), Sudáfrica. La muestra consistió en 276 hombres y 204 mujeres, de 1 a 25 años y de dos grupos de población, negro africano y blanco. Se utilizó el software SLICER 3D (www.slicer.org) para reconstruir un modelo 3D del seno aéreo. Se clasificaron rasgos morfológicos como la presencia del seno aéreo, festoneado y septos dentro de los senos. Además, se analizó la forma del modelo 3D del seno anterior (coronal) y lateral (sagital) adaptando las clasificaciones de Kim (1962) y Kim *et al.* (2002). El seno maxilar estaba presente bilateralmente en n = 477 individuos (99,4 %). Se encontraron cinco diferentes formas anteriores: Tipo 1 (triangular), Tipo 2 (triángulo invertido), Tipo 3 (cuadrado), Tipo 4 (irregular) y Tipo 5 (rectangular) fueron identificados en la vista anterior. Esta forma se asoció con la edad y los grupos de población (p < 0,05). En la vista lateral, el seno maxilar parecía cuadrilátero con diferencias observadas a lo largo de la pared inferior. Los septos maxilares fueron más evidentes en la región anterior del seno maxilar (27,9 % derecho y 28,5 % izquierdo). Los septos maxilares eran más frecuentes en las mujeres (37,9 % derecho, 39,4 % izquierdo) que en los varones (28,5 % derecho y 30,3 % izquierdo). También se observaron más comúnmente en la cohorte blanca (63,8 % derecho, 68,1 % izquierda) que en la cohorte africana negra (29,1 % derecho y 30,5 % izquierda). También se observó la festoneación en el plano axial desde arriba a lo largo de su margen anterior. Se estableció una clasificación en profundidad de la morfología de la forma tridimensional del seno maxilar según la edad (1 a 25 años). Se observaron cinco formas diferentes tanto en la vista anterior como en la lateral del modelo 3D. Anteriormente, se observó que la forma principal era el Tipo 2 (triángulo invertido). La forma del seno cambia según la edad. Lateralmente, la forma estaba relacionada con el desarrollo de los dientes, ya que se clasificó la pared inferior del seno maxilar. Los septos maxilares y la festoneación del seno maxilar se encontraron en todos los grupos de edad. Desde el punto de vista quirúrgico, el conocimiento de la morfología del seno maxilar es esencial al momento de realizar procedimientos dentales como el aumento del seno o los implantes dentales, y antropológicamente, en la identificación forense.

PALABRAS CLAVE: Reconstrucción 3D; Morfología; Forma; Seno maxilar.

REFERENCES

- Adibelli, Z. H.; Songu, M. & Adibelli, H. Paranasal sinus development in children: A magnetic resonance imaging analysis. *Am. J. Rhinol. Allergy*, 25(1):30-5, 2011.
- Fernandes, C. L. Forensic ethnic identification of crania: the role of the maxillary sinus--a new approach. *Am. J. Forensic Med. Pathol.*, 25(4):302-13, 2004.

- González-Santana, H.; Peñarrocha-Diago, M.; Guarinos-Carbó, J. & Sorní-Bröker, M. A study of the septa in the maxillary sinuses and the subnasal alveolar processes in 30 patients. *J. Oral Implantol.*, 33(6):340-3, 2007.
- Holton, N.; Yokley, T. & Butaric, L. The Morphological interaction between the nasal cavity and maxillary sinuses in living humans. *Anat. Rec.*, 296(3):414-26, 2013.
- Jun, B. C.; Song, S. W.; Park, C. S.; Lee, D. H.; Cho, K. J. & Cho, J. H. The analysis of maxillary sinus aeration according to aging process; volume assessment by 3-dimensional reconstruction by high-resolution CT scanning. *Otolaryngol. Head Neck Surg.*, 132(3):425-34, 2005.
- Kim, G. R. A morphological study of the paranasal sinuses in Koreans. *Yonsei Med. J.*, 3(1):11-7, 1962.
- Kim, H. J.; Yoon, H. R.; Kim, K. D.; Kang, M. K.; Kwak, H. H.; Park, H. D.; Han, S. H. & Park, C. S. Personal-computer-based three-dimensional reconstruction and simulation of maxillary sinus. *Surg. Radiol. Anat.*, 24(6):392-8, 2002.
- Laitman, J. T. Harnessing the hallowed hollows of the head: the mysterious world of the paranasal sinuses. *Anat. Rec. (Hoboken)*, 291(11):1346-9, 2008.
- Levine, H. L. & Clemente, M. P. *Sinus Surgery: Endoscopic and Microscopic Approaches*. New York, Thieme, 2005.
- Malec, M.; Smektaa, T.; Trybek, G. & Sporniak-Tutak, K. Maxillary sinus septa: prevalence, morphology, diagnostics and implantological implications. Systematic review. *Folia Morphol. (Warsz.)*, 73(3):259-66, 2014.
- Malec, M.; Smektaa, T.; Tutak, M.; Trybek, G. & Sporniak-Tutak, K. Maxillary sinus septa prevalence and morphology-computed tomography based analysis. *Int. J. Morphol.* 33(1):144-8, 2015.
- Orhan, K.; Kusacki Seker, B.; Aksoy, S.; Bayindir, H.; Berberoglu, A. & Seker, E. Cone beam CT evaluation of maxillary sinus septa prevalence, height, location and morphology in children and an adult population. *Med. Princ. Pract.*, 22(1):47-53, 2013.
- Park, Y. B.; Jeon, H. S.; Shim, J. S.; Lee, K. W. & Moon, H. S. Analysis of the anatomy of the maxillary sinus septum using 3-dimensional computed tomography. *J. Oral Maxillofac. Surg.*, 69(4):1070-8, 2011.
- Scuderi, A. J.; Harnsberger, H. R. & Boyer, R. S. Pneumatization of the paranasal sinuses: normal features of importance to the accurate interpretation of CT scans and MR images. *A. J. R. Am. J. Roentgenol.*, 160(5):1101-4, 1993.
- Shahidi, S.; Zamiri, B.; Momeni Danaei, S.; Salehi, S. & Hamedani, S. Evaluation of anatomic variations in maxillary sinus with the aid of cone beam computed tomography (CBCT) in a population in south of Iran. *J. Dent. (Shiraz)*, 17(1):7-15, 2016.
- Sperber, G. H. *Craniofacial Embryology*. 4th ed. London, Wright Publishing Co., 1989.
- Standring, S. *Gray's Anatomy. The Anatomical Basis of Clinical Practice*. 41st ed. Philadelphia, Elsevier Limited, 2016.
- Wolf, G.; Anderhuber, W. & Khan, F. Development of the paranasal sinuses in children: implications for paranasal sinus surgery. *Ann. Otol. Rhinol. Laryngol.*, 102(9):705-11, 1993.

Corresponding author:
Professor KS Satyapal
Department of Clinical Anatomy
School of Laboratory Medicine and Medical Sciences
College of Health Sciences
University of KwaZulu-Natal
Private Bag X54001

Durban 4000
SOUTH AFRICA

Received:05-02-2017
Accepted:09-06-2017

E-mail address : satyapalk@ukzn.ac.za