

Anatomic Measurement and Clinical Significance of the Middle and Lower Thoracic Segments in Normal Adults

Medición Anatómica e Importancia Clínica de los Segmentos Torácico Medio e Inferior en Adultos Normales

Yangyang Xu¹; Mingjie Gao¹; Yongqiang Cai¹; Lidong Wang²; Yunfeng Zhang³;
Huanhuan Guan¹; Baoke Su¹; Xiaohe Li¹; Yidang Wang¹; Kai Zhang⁴ & Haiyan Wang¹

XU, Y.; GAO, M.; CAI, Y.; WANG, L.; ZHANG, Y.; GUAN, H.; SU, B.; LI, X.; WANG, Y.; ZHANG, K. & WANG, H. Anatomic measurement and clinical significance of the middle and lower thoracic segment in normal adults. *Int. J. Morphol.*, 38(4):1090-1095, 2020.

SUMMARY: Thoracic disc herniation (TDH) has high technical difficulty and serious complications, and the clinical anatomy of thoracic intervertebral foramen is less. Collecting 10 adult male cadavers, measuring the longitudinal diameter of the dorsal root ganglion (D_1), the transverse diameter of the dorsal root ganglion (D_2), horizontal sagittal diameter of the upper edge of the intervertebral disc (S_1), the high of intervertebral foramen (H_1), the height of articulationes costovertebrales (H_2), the height of intervertebral disk (H_3), the angle of the dorsal root ganglion (α). The aim of this study is to explore the safe area of middle and lower thoracic section and provide anatomical basis for the selection of operative cannula. Mastering the certain rules of the anatomical structure of the middle and lower thoracic segments, and referring to the above parameters in clinical, is conducive to the selection of the working casing during surgery.

KEY WORDS: Thoracic disc herniation; thoracic vertebra; Anatomic measurement; Foramen intervertebrale.

INTRODUCTION

Disc herniation is one of the most common causes of radiculopathy and myelopathy, most commonly in the lumbar and cervical spine (Ma *et al.*, 2013). Compared with cervical and lumbar vertebrae, TDH is relatively rare in the clinic, and the incidence of symptomatic TDH is about 0.001%, accounting for only about 4 % of all cases of disc herniation (Hott *et al.*, 2005; Quint *et al.*, 2012; Oppenlander *et al.*, 2013; Yoshihara *et al.*, 2014; Zhang *et al.*, 2017). Although the incidence of TDH is very low, it can occur in different segments of the thoracic spine and is more common in the middle and lower thoracic spine (Rohde & Kang, 2004) 75 % of TDH occurs between T8 and T12, and only 4 % of TDH is located above T3 to T4 (Gille *et al.*, 2006). TDH is most common among adults between the ages of 30 and 60, with equal male to female ratios (Hurley *et al.*, 2017; Court *et al.*, 2018). Compared with patients with cervical and lumbar disc herniation, TDH patients have more postoperative complications, which increases the complexity of TDH treatment (Cloney *et al.*, 2018). The concept of

“safety triangle” for lumbar spine surgery was first proposed by Kambin *et al.* (1998) and has been recognized by clinicians it is described as a triangular stereoscopic structure surrounded by four boundary lines. The lower end is the upper endplate of the lower vertebral body, the inner boundary is the dural sac/travel nerve root, the posterior margin is the facet joint, and the outer upper boundary is the travel nerve root. This study explores whether there is a safe operating area for the thoracic spine that is similar to the lumbar spine to increase the success rate of thoracic surgery and provide the working cannula parameters for surgery. There have been a large number of anatomical studies on the cervical and lumbar spine, but there is still little literature on the anatomy of the thoracic intervertebral foramen only some case reports and clinical studies were retrieved. In order to reduce iatrogenic injury and improve the success rate of surgery, the study of anatomy knowledge of thoracic intervertebral foramen is essential for successful operation in this area.

¹The department of Human Anatomy (Digital Medical Center), Inner Mongolia Medical University, Hohhot, 010059, China.

²Department of CT, Inner Mongolia International Mongolia Medical Hospital, Hohhot, 010017, China.

³The department of CT, The second affiliated hospital of Inner Mongolia Medical University, Hohhot, 010017, China.

⁴Department of Orthopedics, The second Hospital of Wulanchabu, Wulanchabu, 010010, China.

Yangyang Xu and Mingjie Gao are first co-author.

MATERIAL AND METHOD

Materials. 10 normal adult fresh cadavers, intact spine (T1 ~ S1), the specific age is unknown, provided by the Human Anatomy Laboratory, School of Basic Medical Sciences, Inner Mongolia Medical University. A total of 20 sides, a total of 340 intervertebral foramen. The morphological structure of the vertebrae has not changed, no bone destruction, no tumors, deformities, fractures, vascular malformations, etc.

Vernier caliper (Japan Mitutoyo, accuracy 0.02 mm), 20 times magnifying glass, bow compass, stainless steel ruler (accuracy 1 mm), medical electric saw drill (Shanghai Bojin Medical Devices Co., Ltd., BYJ-1) surgical instruments: scalpel, surgical scissors, hemostatic forceps, anatomical tweezers, hacksaw.

Preparation of specimen. Dissecting the chest and lumbar segments of 10 adult cadaver specimens, removing the internal organs, and cut the spine specimens horizontally from the upper end of the hacksaw, identify the lumbar section, marked by the 12th rib, the lower end is horizontally disconnected from the hip joint, and then the local solution is performed, remove the skin and muscles and surrounding soft tissue structure, carefully remove the psoas muscle, clearly and completely expose the entire thoracic vertebrae, lumbar vertebrae, intervertebral disc, intervertebral foramen nerve root structure, keep the nerve roots in the intervertebral foramen without changes, perform intervertebral foramen, Morphological observation of nerve roots and intervertebral discs. The upper end of the scalpel was disconnected from the C7/T1 segmental disc, and the lower end was self-use medical electric saw to drill the rib and thoracic vertebrae along the rib joint.

Measuring method. The longitudinal diameter of the dorsal root ganglion (D_1): Maximum distance between the axial edges of the ganglion; the transverse diameter of the dorsal root ganglion (D_2): Maximum distance between the edges of the D_1 ganglion; horizontal sagittal diameter of the upper edge of the intervertebral disc (S_1). The vertical distance between the upper edge of the disc and the posterior edge of the intervertebral foramen; the high of intervertebral foramen (H_1). The distance between the lower edge of the superior pedicle and the upper edge of the lower pedicle; the height of articulationes costovertebrales (H_2): Intercortical distance of articulationes costovertebrales; the height of intervertebral disk (H_3): left high (h_1), left rib cephalic

ventral disc height, right high (h_2), right rib cephalic ventral disc height; middle height (h_3), spinal axis intervertebral disc height, the angle of the dorsal root ganglion (α): the angle between the nerve root and the spinal canal (Fig. 1).

Statistical Analysis. All statistical analysis was performed using SPSS 21.0 (IBM Corporation, Armonk, NY, USA): The measurement data were expressed as mean \pm standard deviation ($\bar{X} \pm s$): paired t test was used between the left and right sides; the same index was analyzed by variance for different segments; $p < 0.05$ was considered significant.

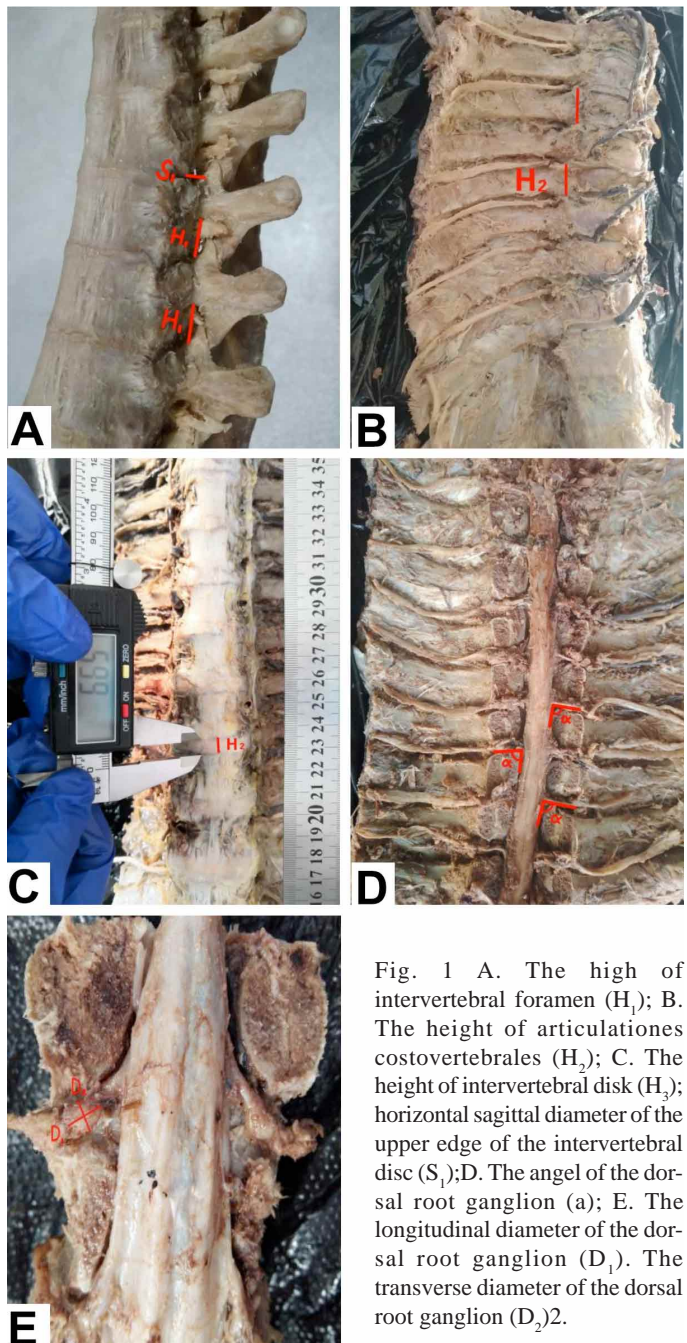


Fig. 1 A. The high of intervertebral foramen (H_1); B. The height of articulationes costovertebrales (H_2); C. The height of intervertebral disk (H_3); horizontal sagittal diameter of the upper edge of the intervertebral disc (S_1); D. The angel of the dorsal root ganglion (α); E. The longitudinal diameter of the dorsal root ganglion (D_1). The transverse diameter of the dorsal root ganglion (D_2).

RESULTS AND DISCUSSION

The longitudinal diameter of the dorsal root ganglion (D_1): the maximum is $T_{10}\sim T_{11}\sim T_7\sim T_8$, smaller in $T_{12}\sim L_1$, increasing trend after increasing. The transverse diameter of the dorsal root ganglion (D_2): no obvious change trend, the maximum is $T_{12}\sim L_1$, smaller in $T_7\sim T_8$; Horizontal sagittal diameter of the upper edge of the intervertebral disc (S_1): the maximum is $T_{11}\sim T_{12}$ and the minimum is $T_7\sim T_8$, trend of increasing first and then decreasing; The high of intervertebral foramen (H_1): larger in $T_8\sim T_9, T_{10}\sim T_{11}, T_{11}\sim T_{12}$, smaller in $T_7\sim T_8$, fluctuating trend; the height of articulationes costovertebrales (H_2): no obvious change trend, larger in $T_9\sim T_{10}, T_{10}\sim T_{11}, T_{12}\sim L_1$, smaller in $T_7\sim T_8$; The height of intervertebral disk (H_3): the maximum is $T_{12}\sim L_1$ and the minimum is $T_7\sim T_8$, increasing trend; The angel of the dorsal root ganglion (a): $T_7\sim T_8$ is greater than 90° , the angle of the segment below T_{10} is obviously reduced to an acute angle, and the middle and lower thoracic segments are decreasing (Tables I to VII).

Table I. The longitudinal diameter of the dorsal root ganglion (D_1) (unit: mm).

Lever	Lift	Right	Bilateral	95 % CI
$T_7\sim T_8$	6.23±0.35	6.37±0.80	6.29±0.86 [#]	5.77~7.35
$T_8\sim T_9$	7.55±1.29	7.59±0.20	7.07±1.02	6.07~7.90
$T_9\sim T_{10}$	7.34±0.73	7.32±1.13	7.33±1.08	5.28~7.90
$T_{10}\sim T_{11}$	8.69±2.34	8.16±0.96	7.93±1.89 [#]	6.72~9.48
$T_{11}\sim T_{12}$	7.81±2.67	6.89±1.48	7.35±2.13	6.47~9.41
$T_{12}\sim L_1$	6.14±2.17	6.59±2.47	6.40±2.28 [#]	7.16~9.90

*Comparison between left and right sides *p<0.05.

#Comparison between different segments. #p<0.05

Table II. The transverse diameter of the dorsal root ganglion (D_2) (unit: mm).

Lever	Lift	Right	Bilateral	95 % CI
$T_7\sim T_8$	4.34±0.80*	4.83±0.72	4.59±0.80	3.50~5.37
$T_8\sim T_9$	5.00±0.86	4.79±0.44	4.89±0.69	4.03~5.53
$T_9\sim T_{10}$	4.80±0.78**	4.48±0.98	4.64±0.90	3.49~5.28
$T_{10}\sim T_{11}$	5.31±0.69	5.12±0.62	5.22±0.66	4.27~5.82
$T_{11}\sim T_{12}$	5.38±0.34	5.28±0.42	5.33±0.38	4.98~5.49
$T_{12}\sim L_1$	5.44±0.37*	5.69±0.30	5.55±0.37	5.33~5.82

*Comparison between left and right sides *p<0.05.

#Comparison between different segments. #p<0.05

Table III. The horizontal sagittal diameter of the upper edge of the intervertebral disc (S_1) (unit: mm).

Lever	Lift	Right	Bilateral	95 % CI
$T_7\sim T_8$	6.01±0.69	6.21±0.92	6.00±0.53	5.32~6.12
$T_8\sim T_9$	6.13±0.56	6.97±0.78	6.55±0.43	5.95~6.87
$T_9\sim T_{10}$	6.75±0.42	7.35±0.43	6.93±0.49	6.50~7.40
$T_{10}\sim T_{11}$	7.22±1.73	7.44±1.46	7.33±1.37	5.60~8.84
$T_{11}\sim T_{12}$	7.40±0.56	7.42±0.82	7.41±0.60	6.87~7.92
$T_{12}\sim L_1$	7.17±1.08	6.78±0.98	6.94±0.53	5.32~7.24

*Comparison between left and right sides *p<0.05.

#Comparison between different segments. #p<0.05

The most common first symptom of TDH is pain, including chest pain, back pain, intercostal neuralgia, another common symptom is numbness or paresthesia. Clinical examination often shows symptoms of central or mixed nerve injury such as sensory disturbance and muscle weakness below the affected plane. The thoracoscopic discectomy surgery is less traumatic, the incidence of intercostal neuralgia is reduced, is the preferred treatment for thoracic intervertebral discs at the center of $T_4\sim T_{11}$ (Elhadi *et al.*, 2015). Posterior thoracic laminectomy with or without discectomy is associated with uniformly poor results and severe neurological complications and has been abandoned. Currently accepted approaches for thoracic disc herniation include (1) posterolateral approaches (transpedicular, costotransversectomy, lateral extracavitary), (2) transthoracic approaches (transpleural, retropleural, thoracoscopic), and (3) ventral approaches (transsternal and manubrial window approach for $T_2\sim T_5$ discs) (Mehdian & Nasto, 2016). Study pointed out that the overall neurological improvement rate of the anterior and posterior approaches is similar, and similarly, the degree of pain improvement is similar (Hurley *et al.*). Study considered that posterior unilateral modified transpedicular pedicled in-segment fixation and interbody fusion is a safe and reproducible method, which can achieve circumferential decompression and segmental stabilization (Carr *et al.*, 2017). The purpose of fusion with the segment.

According to the literature, there are many studies on the anatomy of the lumbar intervertebral foramen, and there are few studies on the intervertebral foramen of the thoracic spine. Vialle *et al.* (2015) performed a lumbar study on 8 adult corpses (average 54 years). The H_1 averaged 15.25 mm, the D_1 averaged 13.25 mm, and D_2 averaged 7.05 mm, the measured value is significantly larger than the measured value of the thoracic vertebra (Leng *et al.*, 2018). Studied the thoracolumbar segment of 24 adult male corpses (average 47 years), the D_1 $T_1\sim L_5$ gradually increased, the most obvious increase in the lumbar segment, the D_2 $T_1\sim T_9$ did not change much, the segment below T_9 gradually increased, and the nerve root and spinal canal axis angles $T_1\sim L_5$ gradually decreased (Leng *et al.*) obtained that the D_1 value is larger than the measured value of this study, which is different from the trend of this study. The D_2 result is consistent with this study and the measured value is similar. The angle between the nerve root and the spinal canal axis is smaller than the angle in this study, the reason is that Leng *et al.* measured one side of the angle as the direction from which the nerve root is emitted from the spinal canal, while the side of the a value in this study is the direction in which the nerve root leaves the

Table IV. The high of intervertebral foramen (H_1) (unit:mm).

Lever	Lift	Right	Bilateral	95 %CI
T ₇ ~T ₈	7.63±1.34	7.76±1.88	7.70±1.54	6.34~7.91
T ₈ ~T ₉	10.40±3.51	10.04±3.00	10.22±3.09#	7.70~10.66
T ₉ ~T ₁₀	10.45±4.29	9.80±4.33	10.13±4.08#	7.12~10.42
T ₁₀ ~T ₁₁	9.97±3.25	10.09±3.80	10.03±3.33#	7.54~10.36
T ₁₁ ~T ₁₂	11.16±1.95	10.47±2.98	10.81±2.40	8.62~10.92
T ₁₂ ~L ₁	8.86±1.09	9.53±1.19	9.20±1.12#	8.04~9.46

*Comparison between left and right sides *p<0.05.

#Comparison between different segments. #p<0.005, ##p<0.001

Table V. Theight of articulationes costovertebrales (unit: mm).

Lever	Lift	Right	Bilateral	95 % CI
T ₇ ~T ₈	13.98±1.78	13.80±1.81	13.87±1.74	12.48~14.79
T ₈ ~T ₉	14.20±2.14	13.57±2.68	13.88±2.37	12.06~15.32
T ₉ ~T ₁₀	14.72±2.08	14.34±3.62	14.53±2.86	12.60~16.39
T ₁₀ ~T ₁₁	14.06±1.23	14.59±2.60	14.33±1.68	13.26~15.26
T ₁₁ ~T ₁₂	14.07±2.01	13.70±2.06	13.90±1.98	13.23~15.53
T ₁₂ ~L ₁	14.84±2.17	14.77±0.92	14.81±1.59	13.59~15.66

*Comparison between left and right sides *p<0.05.

#Comparison between different segments. #p<0.05

Table VI. The height of intervertebral disk (H_3) (unit:mm)

Lever	Lift	Middle	Right	Mean	95 % CI
T ₇ ~T ₈	5.98±1.12	5.07±0.59	5.28±0.66	5.44±0.93#	4.95~6.15
T ₈ ~T ₉	5.79±0.82	5.18±0.66	5.92±1.08	5.60±0.88#	5.01~6.19
T ₉ ~T ₁₀	6.94±0.99*	4.84±0.65	6.17±0.58	5.97±1.23#	5.14~6.79
T ₁₀ ~T ₁₁	6.69±1.43*	6.42±1.14	8.66±1.65	7.13±1.69#	5.99~8.26
T ₁₁ ~T ₁₂	9.30±1.17	8.02±2.15	9.11±0.91	8.78±1.65##	7.67~9.89
T ₁₂ ~L ₁	9.29±1.97	8.92±2.18	8.93±0.65	9.06±1.64##	7.95~10.16

*Comparison between left and right sides *p<0.05.

#Comparison between different segments. #p<0.05

Table VII. The angle of the dorsal root ganglion (α) (unit:°)

Lever	Lift	Right	Bilateral	95 % CI
T ₇ ~T ₈	92.07±4.03*	83.30±5.75	87.68±6.54	80.82~94.54
T ₈ ~T ₉	89.43±1.12	84.53±7.27	86.98±5.37	81.35~92.62
T ₉ ~T ₁₀	85.90±7.21	81.80±7.06	83.85±6.77	76.75~90.95
T ₁₀ ~T ₁₁	88.33±0.80	85.00±6.70	86.67±4.64	81.80~91.54
T ₁₁ ~T ₁₂	76.57±2.01	73.17±3.53	74.87±3.17	71.54~78.20
T ₁₂ ~L ₁	65.40±1.01	67.00±2.31	65.46±3.17	60.24~66.65

*Comparison between left and right sides *p<0.05.

#Comparison between different segments. #p<0.05

intervertebral foramen. Studied 16 corpses, 10 females and 6 males (68~106 years old) lumbar vertebrae: At L₅, D₂ is at most 6.5 mm; the value of α is the smallest on the left side of L₅ (50.50~58.80)°, and the right side of L₄ (50.50~57.20)°, and measure the distance between adjacent pedicles (similar to H₁ in this study) L₁~L₅ (7.2~10.3) mm. Maximum distance from the disc to the posterior margin of the intervertebral foramen (similar to S₁ in this study) L₁~L₅ (6.6~8.7mm) (Silverstein *et al.*, 2015). The ganglion measurements are significantly larger than this study. Silav *et al.* (2016) measured the waist D₁ average L₁ 5.39 mm; L₂ 5.83 mm; L₃ 7.24 mm; L₄ 7.97 mm and L₅ was 10.83

mm. D₂ average L₁ 4.36mm; L₂ 4.56 mm; L₃ 4.99 mm; L₄ 5.22 mm and L₅ 5.82 mm. D₁ and D₂ gradually increased from L₁ to L₅ and the lumbar nerve roots were significantly larger than the thoracic spine measurements in this study. Arslan *et al.* (2012) studied and measured 14 formalin-fixed corpses, and obtained lumbar H₁ L₁~L₅ (17.3~24.3) mm, which was significantly larger than the measured value of this study. For the lumbar vertebrae, the measured values are larger than the thoracic vertebrae, which makes the surgical safety area through the lumbar intervertebral foramen large, and the difficulty coefficient is lower than that of the thoracic vertebra. However, the study of the fine anatomical structure of the thoracic intervertebral foramen is of great significance and value.

Most of TDH occurs in the middle and lower thoracic vertebrae (between T₈ and T₁₂) (Gille *et al.*; Angevine & McCormick, 2012), causing the anterior or anterolateral optic nerve (Arce & Dohrmann, 1985; Cornips *et al.*, 2011). Although the mechanism of TDH is not fully understood, some researchers believe that TDH may be caused by the relative weakness of the posterior longitudinal ligament and the high mobility of the lower thoracic spine (Dickman *et al.*, 1999; Melissano *et al.*, 2009). The potentially serious consequence of TDH is myelopathy, which is characterized by severe lower limb sensation and movement disorders. Thoracic spinal cord disease may have catastrophic and irreversible neurological consequences if not diagnosed and treated promptly and appropriately (Brown *et al.*, 1992; Hou *et al.*, 2016). Because the clinical symptoms caused by cervical and lumbar lesions are similar, and often misdiagnosed, making it difficult to diagnose, which may delay surgical intervention and lead to permanent disability (Smith *et al.*, 2013; Takenaka *et al.*, 2014). Thoracoscopic discectomy has been developed in recent years. This is a new technique for T₄~T₁₂ discectomy, which gradually replaces traditional thoracotomy. However, this method requires advanced technology and equipment and is difficult to promote and popularize (Yamasaki *et al.*, 2013; Kerezoudis *et al.*, 2018). Thoracic anatomy research is essential for exploring safe and reliable surgical approaches.

In this study, the ribs of the $T_7\sim T_9$ segments blocked the intervertebral foramen, while the $T_{10}\sim T_{12}$ had no ribs and the field of view was wider. The size of the cannula depends on S1, because H1 is larger than S1, so the middle and lower thoracic segments allow a 6 mm cannula to pass. The posterior edge of the intervertebral disc constitutes the lower part of the leading edge of the intervertebral foramen, and the nerve roots travel from the upper part of the intervertebral foramen because the vertebrae grow faster than the spinal nerve. If the central disc of the disc will compress the spinal cord and the posterior lateral projection, it will compress the nerve or / and the spinal cord. For the angle α , throughout the entire spine, from the cervical vertebrae to the lumbar vertebrae, the angle experiences an obtuse angle, a right angle, and an acute angle. Lumbar vertebrae can find an obvious "safety triangle", but in this study, the angle of the thoracic vertebrae is more than a right angle, and it is impossible to determine the obvious "safety triangle", which theoretically expands the operable surgical area, the area under the spinal nerves is allowed, so the angle and position of the surgical approach become the focus and key.

CONCLUSION

Thoracic disc herniation remains a challenging procedure? key factors for preoperative decision making include the anatomical location of the herniated disc and the functional status of the patient and the surgeon's experience. Among them, the doctor's understanding of the anatomy of the thoracic spine is the key to surgery. Although the anatomical measurement of the parameters of 10 adult intact spine specimens for intervertebral foramen surgery is carried out, the sample size is less in this study. The sample size will be expanded in the next step, in order to summarize the more valuable parameters and provide reference data for clinical treatment.

ACKNOWLEDGMENTS

This study was supported by Study on the Natural Science Foundation of China (81460330,81860382, 81860383,81560348,81660358), the Youth Elite of Science and technology of Inner Mongolia Autonomous Region Colleges and Universities "Young Science and Technology Talents Program", No. NJYT-15-B05 (to LXH); the Inner Mongolia Autonomous Region Science and Technology Plan Project (2016) (to LXH); the Natural Science Foundation of Inner Mongolia Autonomous Region, No. 2016MS08131 (to LXH); the Science and Technology Innovation Leading Project of Inner Mongolia Autonomous Region (2017) (to

LXH); the Fund for Returnees from the Department of Human Resources and Social Security of Inner Mongolia Autonomous Region (to LXH)

XU, Y.; GAO, M.; CAI, Y.; WANG, L.; ZHANG, Y.; GUAN, H.; SU, B.; LI, X.; WANG, Y.; ZHANG, K. & WANG, H. Medición anatómica e importancia clínica del segmento torácico medio e inferior en adultos normales. *Int. J. Morphol.*, 38(4):1090-1095, 2020.

RESUMEN: La hernia de disco torácico (TDH) tiene una alta dificultad técnica y complicaciones graves, y la anatomía clínica del agujero intervertebral torácico es menor. Recolectando 10 cadáveres machos adultos, midiendo el diámetro longitudinal del ganglio de la raíz dorsal (D_1), el diámetro transversal del ganglio de la raíz dorsal (D_2), el diámetro sagital horizontal del borde superior del disco intervertebral (S1), el colmo del intervertebral agujero (H_1), la altura de las articulaciones costovertebrales (H_2), la altura del disco intervertebral (H_3), el ángel del ganglio de la raíz dorsal (α). El objetivo de este estudio es explorar el área segura de la sección torácica media y baja y proporcionar una base anatómica para la selección de la cánula operatoria. Dominar ciertas reglas de la estructura anatómica de los segmentos torácicos medio e inferior, y referirse a los parámetros anteriores en clínica, es propicio para la selección de la carcasa de trabajo durante la cirugía.

PALABRAS CLAVE: Hernia de disco torácico; Vértebra torácica; Medición anatómica Foramen intervertebral.

REFERENCES

- Angevine, P. D. & McCormick, P. C. Thoracic disc. *J. Neurosurg. Spine*, 16(3):261-2, 2012.
- Arce, C. A. & Dohrmann, G. J. Herniated thoracic disks. *Neurol. Clin.*, 3(2):383-92, 1985.
- Arslan, M.; Cömert, A.; Açar, H. I.; Ozdemir, M.; Elhan, A.; Tekdemir, I.; Tubbs, R. S. & Ugur, H. Ç. Nerve root to lumbar disc relationships at the intervertebral foramen from a surgical viewpoint: An anatomical study. *Clin. Anat.*, 25(2):218-23, 2012.
- Brown, C. W.; Deffer, P. A. Jr.; Akmakjian, J.; Donaldson, D. H. & Brugman, J. L. The natural history of thoracic disc herniation. *Spine*, 17(6 Suppl.):S97-102, 1992.
- Carr, D. A.; Volkov, A. A.; Rhoiney, D. L.; Setty, P.; Barrett, R. J.; Claybrooks, R.; Bono, P. L.; Tong, D. & Soo, T. M. Management of thoracic disc herniations via posterior unilateral modified transfacet pedicle-sparing decompression with segmental instrumentation and interbody fusion. *Global Spine J.*, 7(6):506-13, 2017.
- Cloney, M.; Hopkins, B.; Dhillon, E. & Dahdaleh, N. S. Outcomes of thoracic discectomy: A single center retrospective series. *J. Clin. Neurosci.*, 48:128-32, 2018.
- Cornips, E. M.; Janssen, M. L. & Beuls, E. A. Thoracic disc herniation and acute myelopathy: clinical presentation, neuroimaging findings, surgical considerations, and outcome. *J. Neurosurg. Spine*, 14(4):520-8, 2011.
- Court, C.; Mansour, E. & Bouthors, C. Thoracic disc herniation: Surgical treatment. *Orthop. Traumatol. Surg. Res.*, 104(1S):S31-S40, 2018.

- Dickman, C. A.; Rosenthal, D. & Regan, J. J. Reoperation for herniated thoracic discs. *J. Neurosurg.*, 91(2 Suppl.):157-62, 1999.
- Elhadi, A. M.; Zehri, A. H.; Zaidi, H. A.; Almefty, K. K.; Preul, M. C.; Theodore, N. & Dickman, C. A. Surgical efficacy of minimally invasive thoracic discectomy. *J. Clin. Neurosci.*, 22(11):1708-13, 2015.
- Gille, O.; Soderlund, C.; Razafimahandri, H. J.; Mangione, P. & Vital, J. M. Analysis of hard thoracic herniated discs: review of 18 cases operated by thoracoscopy. *Eur. Spine J.*, 15(5):537-42, 2006.
- Hott, J. S.; Feiz-Erfan, I.; Kenny, K. & Dickman, C. A. Surgical management of giant herniated thoracic discs: analysis of 20 cases. *J. Neurosurg. Spine*, 3(3):191-7, 2005.
- Hou, X.; Sun, C.; Liu, X.; Liu, Z.; Qi, Q.; Guo, Z.; Li, W.; Zeng, Y. & Chen, Z. Clinical features of thoracic spinal stenosis-associated myelopathy: a retrospective analysis of 427 cases. *Clin. Spine Surg.*, 29(2):86-9, 2016.
- Hurley, E. T.; Maye, A. B.; Timlin, M. & Lyons, F. G. Anterior versus posterior thoracic discectomy: a systematic review. *Spine (Phila Pa 1976)*, 42(24):E1437-E1445, 2017.
- Kambin, P.; O'Brien, E.; Zhou, L. & Schaffer, J. L. Arthroscopic microdiscectomy and selective fragmentectomy. *Clin. Orthop. Relat. Res.*, (347):150-67, 1998.
- Kerezoudis, P.; Rajjoub, K. R.; Goncalves, S.; Alvi, M. A.; Elminawy, M.; Alamoudi, A.; Nassr, A.; Habermann, E. B. & Bydon, M. Anterior versus posterior approaches for thoracic disc herniation: Association with postoperative complications. *Clin. Neurol. Neurosurg.*, 167:17-23, 2018.
- Leng, L.; Liu, L. & Si, D. Morphological anatomy of thoracolumbar nerve roots and dorsal root ganglia. *Eur. J. Orthop. Surg. Traumatol.*, 28(2):171-6, 2018.
- Ma, D.; Liang, Y.; Wang, D.; Liu, Z.; Zhang, W.; Ma, T.; Zhang, L.; Lu, X. & Cai, Z. Trend of the incidence of lumbar disc herniation: decreasing with aging in the elderly. *Clin. Interv. Aging*, 8:1047-50, 2013.
- Mehdian, H. & Nasto, L. A. Surgical management of thoracic disc herniation. *Eur. Spine J.*, 25(Suppl. 4):483-5, 2016.
- Melissano, G.; Bertoglio, L.; Civelli, V.; Amato, A. C.; Coppi, G.; Civilini, E.; Calori, G.; De Cobelli, F.; Del Maschio, A. & Chiesa, R. Demonstration of the Adamkiewicz artery by multidetector computed tomography angiography analysed with the open-source software OsiriX. *Eur. J. Vasc. Endovasc. Surg.*, 37(4):395-400, 2009.
- Oppenlander, M. E.; Clark, J. C.; Kalyvas, J. & Dickman, C. A. Surgical management and clinical outcomes of multiple-level symptomatic herniated thoracic discs. *J. Neurosurg. Spine*, 19(6):774-83, 2013.
- Quint, U.; Bordon, G.; Preissl, I.; Sanner, C. & Rosenthal, D. Thoracoscopic treatment for single level symptomatic thoracic disc herniation: a prospective followed cohort study in a group of 167 consecutive cases. *Eur. Spine J.*, 21(4):637-45, 2012.
- Rohde, R. S. & Kang, J. D. Thoracic disc herniation presenting with chronic nausea and abdominal pain. A case report. *J. Bone Joint Surg. Am.*, 86(2):379-81, 2004.
- Silav, G.; Arslan, M.; Comert, A.; Acar, H. I.; Kahilogullari, G.; Dolgun, H.; Tubbs, R. S. & Tekdemir, I. Relationship of dorsal root ganglion to intervertebral foramen in lumbar region: an anatomical study and review of literature. *J. Neurosurg. Sci.*, 60(3):339-44, 2016.
- Silverstein, M. P.; Romrell, L. J.; Benzel, E. C.; Thompson, N.; Griffith, S. & Lieberman, I. H. Lumbar dorsal root Ganglia location: an anatomic and MRI assessment. *Int. J. Spine Surg.*, 9:3, 2015.
- Smith, J. S.; Eichholz, K. M.; Shafizadeh, S.; Ogden, A. T.; O'Toole, J. E. & Fessler, R. G. Minimally invasive thoracic microendoscopic discectomy: surgical technique and case series. *World Neurosurg.*, 80(3-4):421-7, 2013.
- Takenaka, S.; Kaito, T.; Hosono, N.; Miwa, T.; Oda, T.; Okuda, S.; Yamashita, T.; Oshima, K.; Ariga, K.; Asano, M.; et al. Neurological manifestations of thoracic myelopathy. *Arch. Orthop. Trauma Surg.*, 134(7):903-12, 2014.
- Vialle, E.; Vialle, L. R.; Contreras, W. & Junior, C. J. Anatomical study on the relationship between the dorsal root ganglion and the intervertebral disc in the lumbar spine. *Rev. Bras. Ortop.*, 50(4):450-4, 2015.
- Yamasaki, R.; Okuda, S.; Maeno, T.; Haku, T.; Iwasaki, M. & Oda, T. Surgical outcomes of posterior thoracic interbody fusion for thoracic disc herniations. *Eur. Spine J.*, 22(11):2496-503, 2013.
- Yoshihara, H. Surgical treatment for thoracic disc herniation: an update. *Spine (Phila Pa 1976)*, 39(6):E406-12, 2014.
- Zhang, J.; Liang, W. D.; Sheng, W. B.; Guo, H. L. & Deng, Q. Posterolateral discectomy and interbody fusion in the treatment of thoracic disc herniation. *Biomed. Res. (India)*, 28(12):5338-43, 2017.

Corresponding author:

Kai Zhang
Department of Orthopedics
The second Hospital of Wulanchabu
Wulanchabu, 010010
CHINA

Email:13704756034@163.com

Corresponding author:

Xiaohe Li
Department of Human Anatomy (Digital Medical Center)
Inner Mongolia Medical University
Hohhot, 010059
CHINA

Email:798242742@qq.com

Corresponding author:

Haiyan Wang
Department of Human Anatomy (Digital Medical Center)
Inner Mongolia Medical University
Hohhot, 010059
CHINA

Email:18647398868@163.com

Received: 23-10-2019

Accepted: 31-01-2020